

Bone allografts and adjuvant cisplatin for the treatment of canine appendicular osteosarcoma in 18 dogs

The results achieved in 18 dogs following the use of frozen bone cortical allografts for limb-sparing resection of non-metastatic canine appendicular osteosarcoma are presented. Three to five cisplatin doses (70 mg/m²) were administered, starting the day after surgery. The mean and median survival times were 478 and 266 days (range 80 to 2611 days), respectively. The survival rate was 94 per cent at three months, 78 per cent at six months, 35 per cent at 12 months, 23 per cent at 18 months and 19 per cent at 24 months; the disease-free interval was 80 to 1246 days (mean 365 days, median 266 days). Lung metastasis developed in 55 per cent of the dogs within one year. Complications were observed in 14/18 dogs (78 per cent), comprising local recurrence (28 per cent), allograft infection (39 per cent) and implant failure (11 per cent). Despite complications, limb sparing is a useful alternative to amputation in selected cases of appendicular osteosarcoma.

E. MORELLO, P. BURACCO,
M. MARTANO, B. PEIRONE,
C. CAPURRO*, A. VALAZZA, D. COTTO†,
R. FERRACINI§ AND M. SORA‡

Journal of Small Animal Practice (2001)
42, 61–66

Department of Patologia Animale,
Via Nizza 52, 10126 Torino (Turin),
Italy

*Institute for Cancer Research,
Largo Rosanna Benzi 10,
16132 Genova (Genoa), Italy

†Practitioner, Lungodora Colletta
147, 10100 Torino, Italy

§Institute for Cancer Research,
Strada Provinciale 142 km 395,
10060 Candiolo, Torino, Italy

E. Morello, P. Buracco, M. Martano
and B. Peirone's current address
is Department of Patologia Animale,
Via Leonardo da Vinci 44,
10095 Grugliasco (Torino), Italy

INTRODUCTION

Osteosarcoma (OSA) represents 85 per cent of all canine primary bone tumours (Jongeward 1985). Its clinical/biological features have been extensively reviewed (Straw and others 1990, O'Brien and others 1993, Ogilvie and Moore 1995). Lung metastasis represents the cause of death within five to 12 months in approximately 90 per cent of dogs with OSA treated solely by amputation (Brodey and Abt 1976, Spodnick and others 1992, MacEwen and Kurzman 1996), probably as a result of micrometastasis already present at the time of surgery (Thompson and Fugent 1992).

OSA is both a local and systemic disease and improvement in survival can be achieved by combining surgery with chemotherapy (Berg and others 1992). If associated with chemotherapy, the type of surgery (amputation versus limb sparing) does not influence survival (Straw and Withrow 1996). Improved survival has been reported following the administration of cisplatin (Shapiro and others 1988,

Kraegel and others 1991, Straw and others 1991, 1994, Berg and others 1992, Thompson and Fugent 1992), doxorubicin (Berg and others 1995), cisplatin alternated with doxorubicin (Mauldin and others 1988), and carboplatin (Bergman and others 1996).

Canine appendicular OSA is commonly treated by amputation. This is a well tolerated procedure, usually free of complications, and even large dogs can function well if no other significant neurological and/or orthopaedic disease is present (O'Brien and others 1993, Straw 1996). Many owners are satisfied with the pet's quality of life after amputation (Carberry and Harvey 1987), but some do not accept this option.

When amputation is not permitted, limb-sparing surgery offers an alternative approach (Wong and others 1986, Vasseur 1987, LaRue and others 1989, Buracco and others 1998, Straw and Withrow 1996). The results have been considered satisfactory both in terms of the animal's quality of life and survival when compared with amputation. Limb sparing usually consists of an 'en bloc' tumour resection and replacement with a fresh-frozen cortical bone allograft, fixed to the host bone with a dynamic compression plate and screws. Arthrodesis of the nearby joint is usually required. Although allografts cannot contribute living cells for osteogenesis, they are able to allow osteoinduction in the recipient and to provide osteoconduction (Stevenson 1993, Newman-Gage 1998).

The purpose of this paper is to present the results achieved with allograft limb sparing and cisplatin for the treatment of non-metastatic appendicular OSA in 18 dogs.

MATERIALS AND METHODS

Eighteen dogs referred to the Veterinary School of Turin between 1991 and 1996 were included in the study. Criteria for inclusion were no clinical or radiological

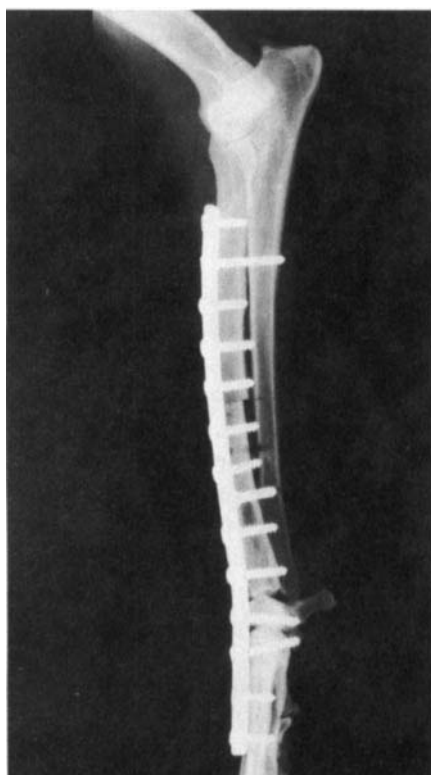


FIG 1. Postoperative radiograph showing application of a cortical allograft following resection of a distal radius osteosarcoma (case 15)

Table 1. Tumour location and case details for the 18 dogs included in the study

Case	Breed	Age (years)	Gender	Tumour location
1	Newfoundland	2.5	M	Distal radius
2	Boxer	10	M	Proximal humerus
3	Schnauzer	9	M	Distal radius
4	Irish wolfhound	5	M	Distal radius
5	Great Dane	8	M	Distal radius
6	German shepherd dog	12	M	Proximal tibia
7	Schnauzer	7	M	Distal radius
8	Neapolitan mastiff	6.5	F	Distal radius
9	German shepherd dog	7	M	Distal radius
10	Irish wolfhound	4	M	Distal tibia
11	German shepherd dog	7	M	Distal radius
12	Rottweiler	8	M	Distal radius
13	Rottweiler	4	M	Distal tibia
14	Boxer	4	F	Distal ulna
15	German shepherd dog	10.5	F	Distal radius
16	Rottweiler	6	F	Distal radius
17	Mixed breed	8	M	Distal femur
18	Husky	2	M	Proximal radius

M Male, F Female

evidence of metastasis at presentation and a histologically confirmed diagnosis of appendicular OSA, not involving more than 50 per cent of the diaphysis. The work-up included history, physical examination, complete blood count, serum biochemical analysis and urinalysis. Radiographic evaluation of the limb (lateral and craniocaudal views) and chest (right and left lateral, and dorsoventral views at inspiration) was performed to examine tumour features and extension, and to look for evidence of pulmonary metastasis. Enlarged regional lymph nodes were aspirated and smears examined cytologically. A biopsy of the bone lesion was obtained using a Jamshidi needle and submitted for histopathology.

A bank of fresh-frozen cortical bone allograft was established. Bones were harvested (with the owners' permission) from animals which had died from trauma and had been assessed to be free from infectious or neoplastic disease. Donors were young to middle-aged large-breed dogs of both sexes. Bones were removed using a standard aseptic surgical procedure. They were aseptically stripped of soft tissues and

periosteum, and the bone marrow was removed by flushing the intramedullary canal with sterile saline. Samples for aerobic and anaerobic culture were taken from the grafts after preparation. Bones were doubled wrapped in sterile plastic bags, identified and stored in a household freezer at -20°C for a maximum of one year. Before use, allografts were thawed in 10 per cent povidone-iodine solution in sterile normal saline, washed with sterile normal saline and resampled for culture as above.

Care was taken to prepare the host limb aseptically to limit bacterial contamination during surgery. Antibiotics (cephazolin 22 mg/kg [Cephamezin; Pharmacia & Upjohn]) were administered intravenously at induction of anaesthesia and every two hours during surgery. Soft tissues were dissected around the tumour, so that most neurovascular structures were present.

The first osteotomy was created with an oscillating bone saw approximately 3 to 4 cm beyond the diaphyseal radiographic margin of the tumour to maximise the likelihood of tumour-free margins. The cut was made perpendicular to the long

axis of the bone to achieve the correct alignment of the allograft with maximal cortical contact. Where there was secondary radiographic and/or macroscopic extension of OSA of the radius to the ulna, the latter was cut together with the radius. The tumour was excised, avoiding gross penetration of the tumour, after disarticulation of the adjacent joint. At this time the diaphyseal host stump bone marrow and the surrounding tissues were cytologically evaluated for neoplastic cells.

The joint was prepared for arthrodesis by thoroughly removing all the articular cartilage followed by flushing with sterile normal saline. The defect was filled with the defrosted cortical bone allograft, modelled to fit the defect and to give maximal contact between graft/host interfaces. The allograft was stabilised using a dynamic compression plate fixed with screws based on the ASIF/AO technique (Perren 1998) (Fig 1). Autogenous cancellous bone, harvested from the ilial wing, was used when the host/graft interface contact was not perfect.

Postoperatively, the surgical site was protected with a modified Robert Jones

Table 2. Clinical history and the results of treatment for the 18 dogs included in the study

Case	Infection	Recurrence	Metastases	Status	Disease-free interval (days)	Survival time (days)	Limb function	Comments	Side effects of chemotherapy
1	None	Y	Y	Dead	80	80	Good		
2	Serious	N	N	Dead	129	129	Poor	Allograft infection: euthanasia	
3	None	N	Y	Dead	140	140	Excellent		
4	Mild	Y	Y	Dead	147	147	Good		Myelosuppression
5	None	N	N	Dead*	180	180	Good	Implant failure due presumably to the excessive length of the allograft: amputation after 26 days. *Gastric dilatation-volvulus	
6	None	N	Y	Dead	205	205	Poor	Poor limb function: amputation after 129 days	
7	None	N	Y	Dead	209	209	Excellent		
8	Slight	N	Y	Dead	213	213	Good		Myelosuppression
9	Mild	N	Y	Dead	216	216	Good		
10	None	N	Y	Dead	316	316	Fair		Renal parameters increased
11	Mild	N	Y	Dead	347	347	Good		Myelosuppression
12	None	Y	N	Dead	354	354	Good	Amputation refused by the owner	
13	None	N	Y	Dead	369	369	Fair	Implant failure: plate replaced	
14	None	Y	N	Dead	396	396	Excellent	Recurrence: amputation after 396 days	Myelosuppression
15	Slight	N	N	Dead*	582	582	Good	*Anal sac adenocarcinoma	
16	Slight	N	N	Dead*	865	865	Good	*Poisoning by pesticides	
17	None	N	N	Dead*	1246	1246	Fair	*Hit by car	Renal parameters increased
18	None	Y	N	Alive	582	2611	Good	Recurrence: amputation after 582 days	

*Death due to tumour-unrelated causes
Y Yes, N No

bandage for seven to 10 days, and antibiotics (cephazolin 22 mg/kg twice daily) were administered for seven to 10 days. Activity was restricted to walking on the lead during the first month.

Adjuvant chemotherapy with cisplatin (Platamine; Pharmacia & Upjohn) was administered intravenously at a dosage of 70 mg/m² in the middle of a six-hour hydration period (rate: 17 ml/kg/hour of saline) every three weeks for three to five treatments, starting the day after surgery. Owing to its potential side effects, peripheral blood cell counts and renal parameters were monitored before each drug administration and after 15 days. Metoclopramide (0.2 to 0.4 mg/kg [Plasil; Lepetit]) was given where nausea and vomiting developed.

All the excised tumours were submitted for histopathological examination to confirm the biopsy diagnosis.

Dogs were reassessed at the Veterinary School of Turin for metastasis, limb function, allograft infection, implant failure, local recurrence and allograft healing on a monthly basis for the first three months and every three months thereafter. Limb

function was evaluated according to a grading system: excellent (slight or no lameness), good (mild lameness), fair (evident lameness) and poor (severe lameness or no use of the limb) function at walk (Peirone and others 1994). The degree of local infection was graded as serious (radiographic evidence of infection of the entire allograft with marked limb swelling, fistulas and no use of the limb), mild (radiographic evidence of localised areas of infection, intermittent fistulas and lameness), and slight (infection of superficial soft tissue, no fistulas, no radiographic evidence of bone involvement and normal limb function).

The survival time referred to in this study corresponds to the interval between surgery and radiographic evidence of lung metastasis and/or any cause of death. In fact, when lung metastasis was detected, no further curative treatment was undertaken and most of these dogs were lost to follow-up. The disease-free period was considered to be the interval between surgery and radiographic evidence of lung metastasis and/or local recurrence.

RESULTS

Fourteen male and four female dogs were included in the study (Table 1). The median age was seven years (range two to 12 years). All dogs were purebred animals of more than 25 kg bodyweight, with the exception of one crossbred dog, which weighed 13 kg. This dog had radiographic signs compatible with bone infarctions, and a possible preneoplastic lesion (Dubielzig and others 1981, Prior and others 1986, Waters and Cooley 1998) in several appendicular bones. The distal radius was the most common site of OSA (11); other tumour locations were the distal tibia (2), proximal humerus (1), proximal tibia (1), distal femur (1), proximal radius (1) and distal ulna (1). None of these dogs had detectable lymphatic metastasis at presentation or developed it later. All OSAs were staged T2N0M0 at presentation (Owen 1980).

The mean and median survival times were 478 and 266 days, respectively (range 80 to 2611 days). The survival rate was 94 per cent (17/18 dogs) at three months after surgery, 78 per cent (14/18 dogs) at

Table 3. Limb function and site of arthrodesis for the 18 dogs

Limb function	Site of arthrodesis			
	Shoulder (one case)	Carpus (11 cases)	Stifle (two cases)	Hock (two cases)
General functional outcome	Limited scapular movements because of the massive muscle detachment and removal	Limited loss of function	Evident circumduction of the limb at walking	Mild circumduction of the limb at walking
Lameness	Evident	None or slight	Severe	Mild
Difficulty rising	Mild	None	Mild to severe depending on the size of dog	Mild

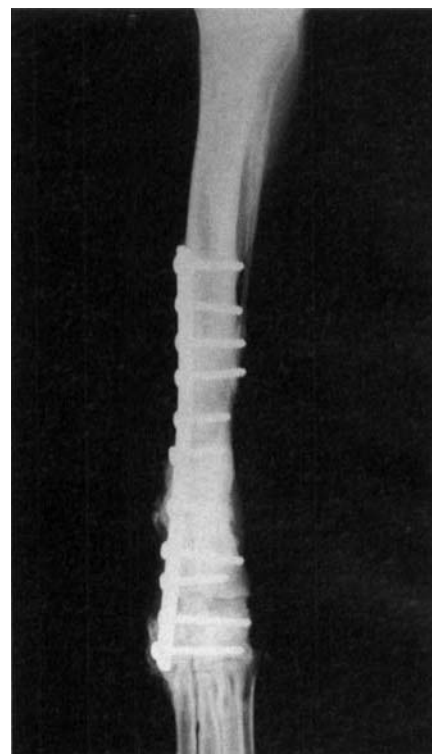

FIG 2. Case 10, 10 months after surgery. Allograft appears well incorporated and a radiodense pattern is prevalent

six months, 35 per cent (6/17 dogs; one was excluded because of tumour-unrelated death) at 12 months, 23 per cent (4/17 dogs) at 18 months and 19 per cent (3/16 dogs; one more dog was excluded because of tumour-unrelated death) at 24 months.

Radiographic evidence of lung metastasis (Table 2) was detected in 55 per cent of the dogs (10 cases), 80 to 369 days after surgery. One dog had radiographic evidence of metastasis within three months (5 per cent), two within six months (11 per cent) and seven within one year (39 per cent). Four dogs (22 per cent) died for reasons unrelated to both OSA and its treatment (Table 2).

The complications (Table 2) that occurred were: local recurrence, allograft infection and implant failure. Five dogs had local recurrence (28 per cent; three in the distal radius, one in the proximal radius and one in the distal ulna) 80 to 582 days after surgery. Three out of five recurrences were observed where OSA originally involved only the radius or ulna and the other bone was not removed; in the other two cases (distal radius OSA), the ulna was removed. Two of these five dogs underwent amputation but one died during surgery, while the second was still alive at the time of writing. Of the remaining three cases, two were euthanased because of concomitant evidence of lung metastasis (owner's decision). The owner refused any

further treatment in the fifth case, and this dog underwent euthanasia after a few days.

Seven dogs (39 per cent) had local infection. This was serious in one dog, and the case was euthanased because the owner refused amputation; in the other six dogs, infection was mild to slight and was controlled within 15 to 30 days of antibiotic administration, according to microbiological and sensitivity tests. Case 4 had both mild infection and local recurrence.

Implant failure occurred in two dogs (11 per cent). In the first (distal tibial allograft), the broken plate was replaced; in the second dog (distal radial allograft), amputation was undertaken (owner's decision).

All dogs received at least three adjuvant doses of cisplatin that were usually well tolerated. At the most, nausea and vomiting were observed during the following two to three days; in these cases metoclopramide was useful in diminishing the intensity of these side effects. In four dogs, the neutrophil count dropped below $3 \times 10^3/\text{ml}$; in these cases, a cephalosporin was given and the cisplatin administration was delayed until the neutrophil count exceeded $3 \times 10^3/\text{ml}$. A slight and transient increase in blood urea nitrogen and creatinine values was recorded in two dogs.

Limb function was good to excellent in 72 per cent of the dogs. Most dogs were able to use the leg within one month of surgery. Limb function was good to excel-

lent for carpal arthrodesis, fair for tarsal (medial plate) arthrodesis and poor for shoulder and stifle arthrodesis, the last depending on the size of the dog. In fact, dog 6 had a hindlimb amputation because it was unable both to rise or walk (Table 3).

Limb radiographs taken during the follow-up period showed an initial bone healing in the form of a periosteal bridging across interfaces four to eight weeks after surgery that usually stopped progressing at 24 weeks. Radiographic union was considered complete when cortical continuity was evident across the graft-host interface and periosteal and endosteal callus underwent active remodelling (within one year) (Fig 2). None of the dogs had the plate removed.

DISCUSSION

Amputation is the elective option in most cases of appendicular OSA and is usually free of complications. In the present study, all dogs' owners were first encouraged toward this procedure, but when it was rejected or when orthopaedic or neurological reasons precluded amputation, limb sparing was considered. Unlike amputation, limb sparing is a costly and technically demanding procedure that requires a dedicated owner and a docile animal. Complications may arise and the owner must be

fully aware of these before proceeding. Despite these aspects, results are often gratifying when cases are carefully selected.

Patients in the study were able to weightbear within a few days of surgery. Limb function depends mostly on the joint involved in the arthrodesis (Table 3). In the authors' experience, the ideal candidates are dogs with distal radius OSA, owing to the limited loss of function after carpal arthrodesis.

In the case of the proximal radius OSA (case 18), a very atypical location, the resection of only the radius resulted in good function despite the fact that a cortical allograft without articular cartilage was used and elbow arthrosis developed subsequently.

Poor limb function was observed in this and other studies (LaRue and others 1989, Kuntz and others 1998) where shoulder and stifle arthrodesis (cases 2, 6) was performed, although small dogs can tolerate this procedure (case 17).

Hock arthrodesis, achieved using a medial plate, resulted in fair function. Better results could have been achieved with a dorsal plate positioning (McKee 1994). An increased complication rate due to the poor soft tissue coverage over the allograft/plate system has been reported following surgery at this site (Straw 1996).

Suitable candidates for limb sparing are dogs with OSA not involving more than 50 per cent of the length of the diaphysis, since a stable host allograft system cannot be achieved if the allograft is too long and only a few screws (less than four) can be inserted in the host bone after OSA removal (Table 2, case 5) (Straw and Withrow 1996).

Recurrence was an important local complication in this series. It never occurred at the allograft/host interface, confirming a complete excision after diaphyseal osteotomy and joint disarticulation. In the author's opinion, the evaluation of recent radiographs, together with intraoperative cytological examination of the host stump bone marrow

smears, represents a reliable method for assessing a free-margin osteotomy. It is presumed that recurrences develop from the undetected extension of the tumour in the surrounding soft tissue and the microscopic involvement of the adjacent bone.

Removal of the paired bone (ulna or radius in the case of distal radius or ulna OSA, respectively) is controversial. Even though its persistence provides stability to the implant system, its removal could prevent a local recurrence arising from the microscopic involvement of the adjacent bone, although no conclusion on this possibility can be drawn from the present series. At the time of writing, no procedure, including cytological analysis, has proved to be fully reliable in detecting microscopic neoplastic involvement of surrounding tissues during surgery. Indeed, even though the cytological analysis was always negative in the present study, recurrences occurred. A reduction of local recurrences (from 27 to 17 per cent) has been obtained through a slow release of cisplatin within the surgical wound (Straw and others 1994).

Other complications encountered in the present study were infection and implant failure. Infection has been attributed to extensive surgical resection and damage to the vascular supply, lengthy procedure duration, implantation of metallic devices in non-vascularised bone, limited soft tissue coverage, chemotherapy, undetected foci of infection somewhere in the body and licking (Straw and Withrow 1996). Measures to prevent infection include aseptic surgical technique, appropriate peri- and intraoperative administration of intravenous antibiotics, and prevention of licking and any other postsurgical trauma.

Different degrees of infection were seen. Recurrent wound drainage was the most frequent form and this was adequately controlled with systemic antibiotics and basic wound management. Only in one dog was this type of infection serious enough to require amputation.

Infection was frustrating but, when slight to mild, it was only associated with

an intermittent mild decrease in limb function. In more severe infections, the local implantation of aminoglycoside-impregnated polymethylmethacrylate beads has been reported to be of value (Dernell and others 1998).

Interestingly, it has been noted (Straw 1996) that dogs which develop infection have a longer survival than those that do not, perhaps due to an increased immune-system stimulation. The use of antibiotic-impregnated polymethylmethacrylate cement placed within the medullary canal should help to decrease the infection rate (O'Brien and others 1993); the bone cement should also limit screw loosening, which can occur during allograft revascularisation and resorption (Straw and Withrow 1996).

Cisplatin was used as an adjuvant treatment in the present study. Emesis, a common sign following cisplatin administration, depends mostly on the dose of the drug used (Ogilvie and others 1989). It has been reported that vomiting can be prevented by not administering the drug pretreatment; metoclopramide was used only to decrease vomiting when this developed in the present study.

Cisplatin was chosen on the basis of previous reports about its efficacy against OSA when combined with surgery (Berg and others 1992, Thompson and Fugent 1992). The authors' results, in terms of median survival, appear similar to those reported by LaRue and others (1989). This finding confirms that, when cisplatin was given, dogs managed by limb sparing had no significant difference in survival compared with those whose limbs were amputated and which had received similar chemotherapy (Shapiro and others 1988, Straw and others 1991). The high metastatic rate, despite chemotherapy, reported in this and other studies, represents the major challenge in the management of OSA. More efforts are needed to find new strategies to limit metastasis. In the present series, the likelihood of development of lung metastasis was higher during the first year postsurgery.

A significant problem encountered in the present study was the availability of allografts, mostly in terms of maintenance of a bank because of both the difficulty of finding appropriate donors and legal restrictions. New approaches to limb sparing have been described, such as the reimplantation of the excised tumour following pasteurisation (Buracco and others 1998) or application of the Ilizarov apparatus (Tommasini Degna and others 2000).

Conclusions

Results obtained from this series are similar to those reported in the literature regarding survival, limb function and complications. Limb sparing is an alternative to amputation in selected cases of appendicular OSA. Although the dogs' owners were not asked to fill in a form on the quality of life of their pet following limb-sparing surgery, their comments were positive, despite the high complication rate related to the technique. This would be in agreement with the oncologist's goals: to treat cancer while assuring a good quality of life in terms of both pain relief and limb function. Complete resection of the tumour is essential for local control and, at the time of writing, adjuvant chemotherapy is the only treatment that addresses metastatic disease and improves overall survival in such cases of OSA.

References

- BERG, J., WEINSTEIN, M. J., SHELLING, S. H. & RAND, W. M. (1992) Treatment of dogs with osteosarcoma by administration of cisplatin after amputation and limb sparing: 22 cases (1987-1990). *Journal of the American Veterinary Medical Association* **200**, 2005-2008
- BERG, J., WEINSTEIN, M. J., SPRINGFIELD, D. S. & RAND, W. M. (1995) Results of surgery and doxorubicin chemotherapy in dogs with osteosarcoma. *Journal of the American Veterinary Medical Association* **206**, 1555-1560
- BERGMAN, P. J., MAC EWEN, E. G., KURZMAN, I. D., HENRY, C. J., HAMMER, A. S., KNAPP, D. W., HALE, A., KRUTH, S. A., KLEIN, M. K., KLAUSNER, J., NORRIS, A. M., MCCAW, D., STRAW, R. C. & WITHROW, S. J. (1996) Amputation and carboplatin for treatment of dogs with osteosarcoma: 48 cases (1991-1993). *Journal of Veterinary Internal Medicine* **10**, 76-81
- BRINKER, W. O., OLMSTEAD, M. L., SUMNER-SMITH, G. & PRIEUR, W. D. (1998) Part 1: general considerations. In: *Manual of Internal Fixation in Small Animals*, 2nd edn. Springer, Berlin
- BRODEY, R. S. & ABT, D. A. (1976) Results of surgical treatment in 65 dogs with osteosarcoma. *Journal of the American Veterinary Medical Association* **168**, 1032-1035
- BURACCO, P., MORELLO, E., MARTANO, M., PEIRONE, B., FERRACINI, R., CAPURRO, C. & RATTO, A. (1998) Results of the use of auto- and allo-bone grafts for the treatment of the canine appendicular osteosarcoma. 18th Veterinary Cancer Society Meeting, Estes Park, CO, USA, October. Abstract book. p 57
- CARBERRY, C. A. & HARVEY, H. J. (1987) Owner satisfaction with limb amputation in dogs and cats. *Journal of the American Animal Hospital Association* **23**, 227-232
- DERNELL, W. S., WITHROW, S. J., STRAW, R. C., POWER, B. E., WEMBER, E. W., JAMESON, V. J., WILKINS, R. M. & ALLEN, R. E. (1998) Clinical response to antibiotic-impregnated polymethyl methacrylate bead implantation of dogs with severe infections after limb-sparing and allograft replacement - 18 cases (1994-1996). *Veterinary and Comparative Orthopaedics and Traumatology* **11**, 94-99
- DUBIELZIG, R. R., BIERY, D. N. & BRODEY, R. S. (1981) Bone sarcomas associated with multifocal medullary bone infarctions in dogs. *Journal of the American Veterinary Medical Association* **179**, 64-68
- JONGEWARD, S. J. (1985) Primary bone tumors. *Veterinary Clinics of North America: Small Animal Practice* **15**, 609-641
- KRAEGEL, S. A., MADEWELL, B. R., SIMONSON, E. & GREGORY, C. R. (1991) Osteogenic sarcoma and cisplatin chemotherapy in dogs: 16 cases (1986-1989). *Journal of the American Veterinary Medical Association* **199**, 1057-1059
- KUNTZ, C. A., ASSELIN, T. L., DERNELL, W. S., POWERS, B. E., STRAW, R. C. & WITHROW, S. J. (1998) Limb salvage surgery for osteosarcoma of the proximal humerus: outcome in 17 dogs. *Veterinary Surgery* **27**, 417-422
- LARUE, S. M., WITHROW, S. J., POWERS, B. E., WRIGLEY, R. H., GILLETTE, E. L., SCHWARZ, P. D., STRAW, R. C. & RITCHER, S. L. (1989) Limb-sparing treatment for osteosarcoma in dogs. *Journal of the American Veterinary Medical Association* **195**, 1734-1744
- MAC EWEN, E. G. & KURZMAN, I. D. (1996) Canine osteosarcoma. Amputation and chemoimmunotherapy. *Veterinary Clinics of North America: Small Animal Practice* **26**, 123-133
- McKEE, M. (1994) Intractably painful joints. In: *Manual of Small Animal Arthrology*, Eds J. E. F. Houlton and R. W. Collison. British Small Animal Veterinary Association, Cheltenham. p 129
- MAULDIN, G. N., MATUS, R. E., WITHROW, S. J. & PATNAIK, A. K. (1988) Canine osteosarcoma treatment by amputation versus amputation and adjuvant chemotherapy using doxorubicin and cisplatin. *Journal of Veterinary Internal Medicine* **2**, 177-180
- NEWMAN-GAGE, H. (1998) Banked allogenic bone grafts: an overview of current theory and uses. In: *Current Techniques in Small Animal Surgery*, 4th edn. Eds M. J. Bojrab, G. W. Ellison and B. Slocum. Williams & Wilkins, Baltimore. pp 910-914
- O'BRIEN, M. G., STRAW, R. C. & WITHROW, S. J. (1993) Recent advances in the treatment of canine appendicular osteosarcoma. *Compendium on Continuing Education for the Practicing Veterinarian* **15**, 939-946
- OGILVIE, G. K. & MOORE, A. S. (1995) Bone tumors. In: *Managing the Veterinary Cancer Patient: A Practice Manual*. Eds G. K. Ogilvie and A. S. Moore. Veterinary Learning System, Trenton, NJ. pp 327-348
- OGILVIE, G. K., MOORE, A. S. & CURTIS C. R. (1989) Evaluation of cisplatin-induced emesis in dogs with malignant neoplasia: 115 cases (1984-1987). *Journal of the American Veterinary Medical Association* **195**, 1399-1403
- OWEN, L. N. (Ed) (1980) Bones and joints. In: *TNM Classification of Tumors in Domestic Animals*. WHO, Geneva. p 44
- PEIRONE, B., TARDY, S., POZZI, L., PIROMALLI, G. & BURACCO, P. (1994) Clinical-functional results of the bone cor-tical implantation for the cure of the appendicular bone malignant tumors: a 3-year experience. 48th Società Italiana Scienze Veterinarie, Abstract book. pp 1945-1948
- PERREN, S. M. (1998) Basic aspects of internal fixation. In: *Manual of Internal Fixation in Small Animals*, 2nd edn. Eds W. O. Brinker, M. L. Olmstead, G. Sumner-Smith and W. D. Prieur. Springer, Berlin. pp 3-56
- PRIOR, C., WATROUS, B. J. & PENFOLD, D. (1986) Radial diaphyseal osteosarcoma with associated bone infarctions in a dog. *Journal of the American Animal Hospital Association* **22**, 43-48
- SHAPIRO, W., FOSSUM, T. W., KITCHELL, B. E., COUTO, C. G. & THEILEN, G. H. (1988) Use of cisplatin for treatment of appendicular osteosarcoma in dogs. *Journal of the American Veterinary Medical Association* **192**, 507-511
- SPODNICK, G. J., BERG, J., RAND, W. M., SCHELLING, S. H., COUTO, C. G., HARVEY, H. J., HENDERSON, R. A., MAC EWEN, G., MAULDIN, N., MACCOW, D. L., MOORE, A. S., MORRISON, W., NORRIS, A. M., O'BRADOVICH, J., O'KEEFE, D. A., PAGE, R., RUSLANDER, D., KLAUSNER, J., STRAW, R. C. & THOMPSON, J. P. (1992) Prognosis for dogs with appendicular osteosarcoma treated by amputation alone: 162 cases (1978-1988). *Journal of the American Veterinary Medical Association* **200**, 995-999
- STEVENSON, S. (1993) Bone grafting. In: *Textbook of Small Animal Surgery*, 2nd edn. Ed D. Slatter. W. B. Saunders, Philadelphia. pp 1694-1703
- STRAW, R. C. (1996) Tumors of the skeletal system. In: *Small Animal Clinical Oncology*, 2nd edn. Eds S. J. Withrow and G. E. MacEwen. W. B. Saunders, Philadelphia. pp 287-315
- STRAW, R. C., WITHROW, S. J., DOULPLE, E. B., BREKKE, J. H., COOPER, M. F., SCHWARZ, P. D., GRECO, D. S. & POWERS, B. E. (1994) The effect of cis-diammine-dichloroplatinum II released from D,L-poly-lactic acid implanted adjacent to cortical allografts in dogs. *Journal of Orthopaedic Research* **12**, 871-877
- STRAW, R. C., WITHROW, S. J. & POWERS, B. E. (1990) Management of canine appendicular osteosarcoma. *Veterinary Clinics of North America: Small Animal Practice* **20**, 1141-1161
- STRAW, R. C., WITHROW, S. J., RICHTER, S. L., POWERS, B. E., KLEIN, M. K., POSTORINO, N. C., LARUE, S. M., OGILVIE, G. K., VAIL, D. M., MORRISON, W. B., MCGEE, M. & DICKINSON, K. (1991) Amputation and cisplatin for treatment of canine osteosarcoma. *Journal of Veterinary Internal Medicine* **5**, 205-210
- STRAW, R. C. & WITHROW, S. J. (1996) Limb-sparing surgery versus amputation for dogs with bone tumors. *Veterinary Clinics of North America: Small Animal Practice* **26**, 135-143
- THOMPSON, J. P. & FUGENT, M. J. (1992) Evaluation of survival times after limb amputation, with and without subsequent administration of cisplatin, for treatment of appendicular osteosarcoma in dogs: 30 cases (1979-1990). *Journal of the American Veterinary Medical Association* **200**, 531-533
- TOMMASINI DEGNA, M., EHRHART, N., FERRETTI, A. & BURACCO, P. (2000) Bone transport osteogenesis for limb salvage following resection of primary bone tumors: experience with six cases (1991-1996). *Veterinary and Comparative Orthopaedics and Traumatology* **13**, 18-22
- VASSEUR, P. V. (1987) Limb preservation in dogs with primary bone tumors. *Veterinary Clinics of North America: Small Animal Practice* **17**, 889-903
- WATERS, D. J. & COOLEY, D. M. (1998) Skeletal neoplasms. In: *Cancer in Dogs and Cats: Medical and Surgical Management*. Ed W. B. Morrison. Williams and Wilkins, Baltimore. pp 639-654
- WONG, A. C. W., AKAHOSHI, Y. & TAKEUCHI, S. (1986) Limb-salvage procedures for osteosarcoma. An alternative to amputation. *International Orthopaedics* **10**, 245-251