

MET Oncogene Aberrant Expression in Canine Osteosarcoma

R. Ferracini, *P. Angelini, *E. Cagliero, †A. Linari,
‡M. Martano, §J. Wunder, and ‡P. Buracco

Divisione di Ortopedia, Ospedale Mauriziano Umberto I. *Institute for Cancer Research, Candiolo
†Divisione di Anatomia Patologica, Ospedale Infantile Regina Margherita, and ‡Dipartimento di
Patologia Animale, Cattedra di Semeiotica Chirurgica, Torino, Italy, and §Musculoskeletal Oncology Unit,
Mount Sinai Medical Center, Toronto, Ontario, Canada

Summary: The objective of this study was to investigate the role of the MET oncogene in canine osteosarcoma. Seven large-breed dogs affected by spontaneous skeletal osteosarcoma underwent *en bloc* tumor excision. Total RNA was extracted from frozen tumor samples and assessed for expression of the MET oncogene by Northern blot analysis. Five of seven biopsy samples expressed high levels of the MET oncogene; its expression in the primary tumors was comparable with that previously identified in primary osteosarcomas in humans. A lung metastasis from one of the dogs expressed MET at a higher level than did its primary tumor. Spontaneously arising osteosarcoma in dogs clinically and pathologically mimics the corresponding disease in humans. We previously demonstrated that the MET oncogene was aberrantly expressed in a high percentage of human osteosarcomas. The results of the current study also provide a molecular parallel between the tumors in dogs and humans. This *in vivo* model may be helpful in evaluating new strategies for therapy against osteosarcoma.

Osteosarcoma of the appendicular skeleton is one of the most life-threatening canine neoplasms. It is typically found in middle-aged, large-breed male dogs. Osteosarcoma most commonly involves the metaphysis of any long bone (except near the elbow), with the distal radius being the most common anatomic site (Fig. 1A). The pathogenesis of canine osteosarcoma is not completely understood; one predisposing factor is excessive body weight and its incidence appears to be increased in certain family lines of large-breed dogs (3). Canine osteosarcoma has the same biological behavior as its human counterpart (28) (Fig. 1B) and historically has been used as an experimental model for therapeutic regimens to be applied to the disease in humans (4,13,28). For example, the literature suggests that micrometastatic disease is present in approximately 90% of dogs at presentation. When possible, canine osteosarcoma is treated with both aggressive surgery (5,25) and adjuvant chemotherapy (1,16). Approximately 50% of dogs survive to 1 year after treatment with this combined approach.

Recent studies investigating the molecular basis of tumor cell invasion and metastasis have identified novel therapeutic approaches based on targeting alterations in normal cellular pathways (12). The MET oncogene has been shown to play an important role in these phenotypic changes (7,15,17). It has been overexpressed or has mutated, or both, in different sporadic and hereditary human carcinomas (20). Its involvement has also been documented as sarcomagenesis (9,18,21). The MET proto-oncogene is the receptor for the cytokine hepatocyte growth factor/scatter factor (HGF), which stimulates the invasive growth of normal and neoplastic cells (9,10,27). In physiological conditions, MET is expressed in cells of epithelial origin whereas its ligand, HGF, is expressed in cells of mesenchymal origin (23).

We previously demonstrated that the MET oncogene was aberrantly expressed in several cases of spontaneous osteosarcomas in humans (9), cell lines of the same origin, and a number of other aggressive mesenchymal neoplasms (21). Moreover, *in vitro* studies demonstrated that osteosarcoma cell lines acquired an invasive phenotype when HGF was added to the culture medium; this further implicates MET in the invasive potential of these tumors (9).

Because of the strong clinical and biological analogy between human and canine osteosarcoma, we

Received July 22, 1998; accepted September 7, 1999.

Address correspondence and reprint requests to R. Ferracini at Institute for Cancer Research (I.R.C.C.), Strada Provinciale 142 Km 3.95, 10060 Candiolo, Torino, Italy. E-mail: RFerracini@irc.unito.it

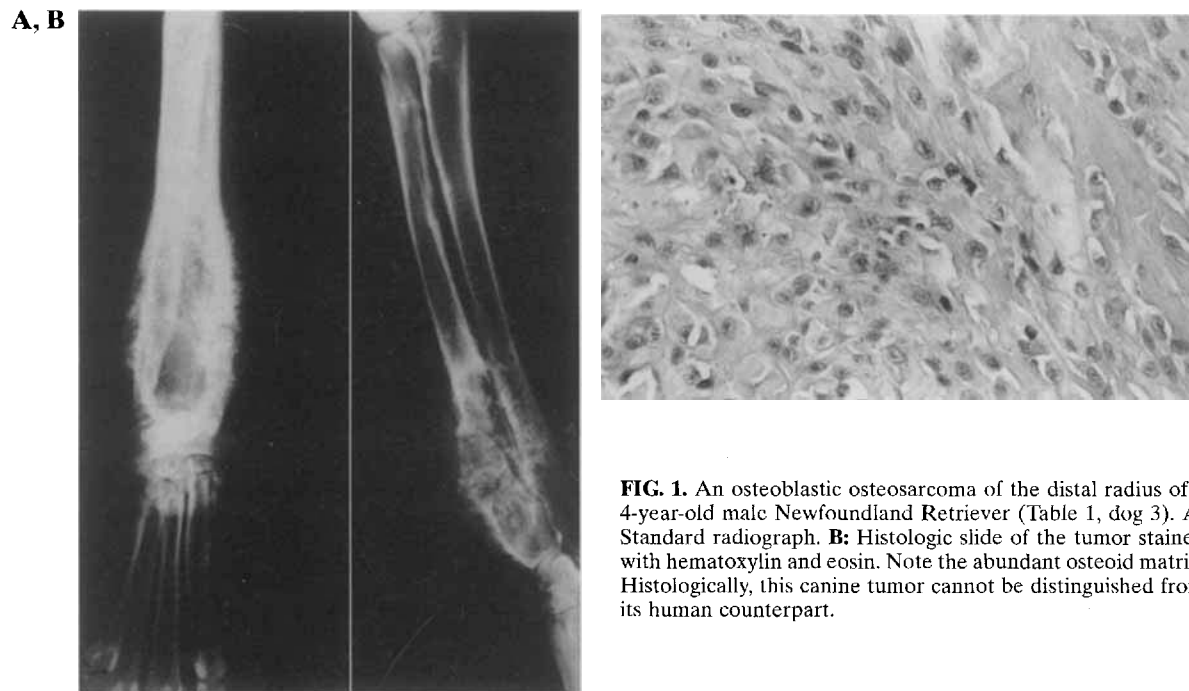


FIG. 1. An osteoblastic osteosarcoma of the distal radius of a 4-year-old male Newfoundland Retriever (Table 1, dog 3). **A:** Standard radiograph. **B:** Histologic slide of the tumor stained with hematoxylin and eosin. Note the abundant osteoid matrix. Histologically, this canine tumor cannot be distinguished from its human counterpart.

assumed that similarities were also present at the molecular level. In this study, we demonstrated that the MET oncogene was frequently expressed at high levels in spontaneous canine osteosarcoma.

MATERIALS AND METHODS

Seven large-breed dogs were diagnosed with skeletal osteosarcoma on the basis of standard radiographs and histologic evaluation of biopsy samples following tumor excision. The mean age was 7.2 years, and the mean weight was 32 kg. Six dogs had localized disease, and one had a solitary lung metastasis at the time of presentation of a primary rib lesion. The dogs had not received treatment for the disease, and all were healthy at the time of diagnosis.

The dogs underwent wide resection of the primary tumor with limb-sparing techniques when applicable (25); the dog with the lung metastasis had this lesion resected at the same time as the primary tumor. Each animal also received adjuvant chemotherapy with doxorubicin at the standard dose (2). Following each surgical procedure, a tumor sample was snap-frozen in liquid nitrogen while an adjacent tumor specimen was examined pathologically to confirm the presence of viable osteosarcoma.

The D17 canine and MG63 human osteosarcoma cell lines were obtained from the American Tissue Culture Collection (reference nos. CLL183 and CRL1427; ATCC, Rockville, MD, U.S.A.). Samples of osteosarcoma were obtained from humans as previously described (9). Total RNA was extracted from the frozen tumor samples and cell lines by the TRI REAGENT method (Sigma Chemical, St. Louis, MO, U.S.A.) (6) and was quantified by spectrophotometry. Fourteen micrograms of RNA from each sample was separated by agarose gel electrophoresis, stained with ethidium bromide, and photographed for densitometry. Northern blot analysis was initially performed (19) with a full-length human MET cDNA probe (9). Subsequently, a glyceraldehyde phosphate dehydrogenase full-length probe was used as an internal control for the quantity and quality of RNA loaded per sample. The level of expression of MET compared with that of glyceraldehyde phosphate dehydrogenase was expressed in arbitrary units relative to a human osteosarcoma biopsy sample that was chosen as a positive control. MET expression in this standard positive control had

been previously confirmed by immunohistochemistry and Western blotting with specific anti-HGF receptor monoclonal antibodies (21).

RESULTS

Total RNA from eight canine osteosarcoma tumor samples and the D17 canine osteosarcoma cell line were analyzed by Northern blot analysis for MET expression (Fig. 2). Five of seven osteosarcoma biopsy samples and the D17 cell line were positive for expression of the MET oncogene (Table 1). The fibroblastic and chondroblastic osteosarcomas had no detectable expression of MET compared with the other subtypes seen on histology. The level of MET expression in the canine tumor samples was comparable with that in a human osteosarcoma chosen as a

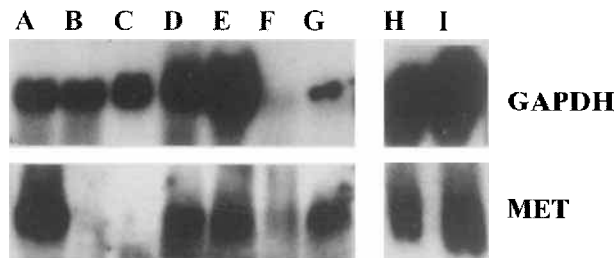


FIG. 2. Northern blot analysis of MET expression in canine osteosarcoma. Lane A: D17 canine osteosarcoma cell line overexpressing MET. Lane B: negative control, normal skeletal muscle. Lane C: negative control, normal tissue from the margin of the surgical excision of the tumor shown in lane D. Lanes D, E, and G: canine osteosarcomas. Lane F: canine fibrosarcoma; this sample did not contain a significant amount of RNA. Lane H: standard positive control from a human osteosarcoma. Lane I: MG63 human osteosarcoma cell line. The upper row shows the internal control gene glyceraldehyde phosphate dehydrogenase (GAPDH), and the lower row shows levels of MET expression.

TABLE 1. *Histological appearance of tumors and expression of MET*

Dog	Localization	Histological appearance	MET ^a
1	Carpus	Telangiectatic	+
2	Rib	Giant cell	+
2	Lung metastasis	Anaplastic	++
3	Distal radius	Osteoblastic	+
4	Proximal tibia	Osteoblastic	+
5	Distal radius	Chondroblastic	-
6	Distal tibia	Osteoblastic	+
7	Distal radius	Fibroblastic	-

^aThe arbitrary level of MET expression denoted by + is similar to the level identified in the standard positive control from a human osteosarcoma (Fig. 2, lane H).

standard positive control (Fig. 2, lane H), as well as in the human MG63 osteosarcoma cell line (Fig. 2, lane I) (9). The lung metastasis from dog 2 expressed MET at a higher level than its corresponding primary tumor (Fig. 2, lane G). In fact, the metastasis was the only tumor specimen to exhibit MET expression at the ++ level (Table 1). No correlation was found between MET expression and the outcome for the dogs. All but one dog died of lung metastases in a period between 5 and 14 months. The surviving animal was alive and disease-free at 35 months follow-up (Table 1, dog 6). Dog 4 (Table 1) did not receive treatment. All the remaining animals underwent surgery and chemotherapy.

DISCUSSION

Specific types of canine malignancies are similar to their human counterparts in histopathologic appearance, biological behavior, and response to therapy. Naturally occurring osteosarcoma in dogs represents a typical model for the disease in humans. Despite recent advances in surgical techniques and chemotherapy protocols, humans with osteosarcoma continue to have a guarded prognosis due to the high risk of systemic recurrence, which occurs in more than 40% of the cases (22). In the canine counterpart, despite aggressive surgery and chemotherapy, most dogs die within 2 years due to the shorter latency period of the disease (24). There is an evident need to increase our knowledge of the molecular characteristics underlying the disease in humans and dogs.

The results of this study verified in the dog model a molecular observation we previously described in human osteosarcoma regarding the aberrant expression of the MET oncogene (21). In terms of analogies of MET function in normal cells, it was previously shown that canine epithelial cells, which express the MET receptor, respond to the human ligand HGF *in*

vitro (8,27) and *in vivo* (14). Furthermore, HGF is ubiquitous in connective tissues and surgical samples of human osteosarcoma (9). These findings suggest that MET receptor function is maintained in both species under normal physiological conditions, as well as in malignancy.

The MET oncogene, which plays an important role in tumor invasion and metastasis in several carcinomas and sarcomas in humans and experimental animals (9), was expressed at high levels in canine osteosarcoma. The number of tumors that overexpressed MET was also comparable with that for the human counterpart (21). Interestingly, the lung metastasis had a higher MET level than did any of the primary tumors. This further supports the role of this oncogene in the processes of invasion and metastasis. Similar to the human model of osteosarcoma, the chondroblastic and fibroblastic subtypes of the disease in dogs were negative for MET expression. These data also correlate with the virtual absence of MET expression in most chondroid and fibroblastic benign and malignant tumors in humans (21). No correlation was found between MET expression and clinical outcome. This might be due to the dismal prognosis of this disease in dogs, regardless of the therapeutic efforts (23).

This study provides an encouraging step in the comparison of human and canine osteosarcoma on a molecular level. On the basis of the evidence, we expect the MET oncogene to play as important a role in the canine system as in its human counterpart. These data, although preliminary, are promising in terms of the development of new diagnostic and therapeutic approaches in veterinary medicine and for the enhancement of comparative oncology in osteosarcoma. Novel interventional strategies—developed *in vitro* and in laboratory studies in animals—for modulating MET expression and receptor function can be tested *in vivo* in dogs with spontaneously occurring tumors. Similar studies might be unacceptable or less feasible in humans with cancer, especially because a standard, yet only partially effective, treatment exists.

Acknowledgment: This work was supported by a grant to R.F. from the Italian Association for Cancer Research. We thank Dr. Giovanna Gambarotta for helpful technical suggestions and Elaine Wright for expert scientific editing.

REFERENCES

1. Berg J, Weinstein MJ, Springfield DS, Rand WM: Results of surgery and doxorubicin chemotherapy in dogs with osteosarcoma. *J Am Vet Med Assoc* 206:1555-1560, 1995
2. Berg J: Canine osteosarcoma: amputation and chemotherapy. *Vet Clin North Am Small Anim Pract* 21:111-121, 1996
3. Brodey RS: Canine bone neoplasms. *J Am Vet Med Assoc* 43:471-495, 1963
4. Brodey RS: The use of naturally occurring cancer in domestic animals for research into human cancer: general considerations and a review of canine skeletal osteosarcoma.

- Yale J Biol Med* 52:345-361, 1979
5. Buracco P, Morello M, Martano M, Peirone B, Ferracini R, Capurro C, Ratto A: Results of the use of auto- and allo-bone graft for the treatment of canine appendicular osteosarcoma. In: *18th Annual Conference Veterinary Cancer Society, October 3-6, 1988, Estes Park, Colorado, Proceedings*, p 57, 1998
 6. Chomczynski P: A reagent for the single-step simultaneous isolation of RNA, DNA and proteins from cell and tissue samples. *Biotechniques* 15:532-537, 1993
 7. Di Renzo MF, Narsimhan RP, Olivero M, Bretti S, Giordano S, Medico E, Gaglia P, Zara P, Comoglio PM: Expression of the Met/HGF receptor in normal and neoplastic human tissues. *Oncogene* 6:1997-2003, 1991
 8. Dremier S, Taton M, Coulonval K, Nakamura T, Matsumoto K, Dumont JE: Mitogenic, dedifferentiating, and scattering effects of hepatocyte growth factor on dog thyroid cells. *Endocrinology* 135:135-140, 1994
 9. Ferracini R, Di Renzo MF, Scotlandi K, Baldini N, Olivero M, Lollini P, Cremona O, Campanacci M, Comoglio PM: The Met/HGF receptor is over-expressed in human osteosarcomas and is activated by either a paracrine or an autocrine circuit. *Oncogene* 10:739-749, 1995
 10. Giordano S, Ponzetto C, Di Renzo MF, Cooper CS, Comoglio PM: Tyrosine kinase receptor indistinguishable from the c-met protein. *Nature* 339:155-156, 1989
 11. Giordano S, Bardelli A, Zhen Z, Menard S, Ponzetto C, Comoglio PM: A point mutation in the MET oncogene abrogates metastasis without affecting transformation. *Proc Natl Acad Sci U S A* 94:13868-13872, 1997
 12. Hahn WC, Counter CM, Lundberg AS, Beijersbergen RL, Brooks MW, Weinberg RA: Creation of human tumour cells with defined genetic elements. *Nature* 400:464-468, 1999
 13. Knapp DW, Waters DJ: Naturally occurring cancer in pet dogs: important models for developing improved cancer therapy for humans. *Mol Med Today* 3:8-11, 1997
 14. Kobayashi Y, Hamanoue M, Ueno S, Aikou T, Tanabe G, Mitsue S, Matsumoto K, Nakamura T: Induction of hepatocyte growth by intraportal infusion of HGF into beagle dogs. *Biochem Biophys Res Commun* 220:7-12, 1996
 15. Maggiora P, Gambarotta G, Olivero M, Giordano S, Di Renzo MF, Comoglio PM: Control of invasive growth by the HGF receptor family. *J Cell Physiol* 173:183-186, 1997
 16. Mauldin GN, Matus RE, Withrow SJ, Patnaik AK: Canine osteosarcoma: treatment by amputation versus amputation and adjuvant chemotherapy using doxorubicin and cisplatin. *J Vet Intern Med* 2:177-180, 1988
 17. Prat MP, Narsimhan RP, Crepaldi T, Nicotra MR, Natali PG, Comoglio PM: The receptor encoded by the human c-MET oncogene is expressed in hepatocytes, epithelial cells and solid tumors. *Int J Cancer* 49:323-328, 1991
 18. Rong S, Bodescot M, Blair D, Dunn J, Nakamura T, Mizuno K, Park M, Chan A, Aaronson S, Vande Woude GF: Tumorigenicity of the Met proto-oncogene and the gene for hepatocyte growth factor. *Mol Cell Biol* 12:5152-5158, 1992
 19. Sambrook J, Fritsch EF, Maniatis T: Northern hybridization. In: *Molecular Cloning*, 2nd ed, section 7.39. Cold Spring Harbor, New York, Cold Spring Harbor Laboratory Press, 1989
 20. Schmidt L, Duh FM, Chen F, Kishida T, Glenn G, Choyke P, Scherer SW, Zhuang Z, Lubensky I, Dean M, Allikmets R, Chidambaram A, Bergerheim UR, Feltis JT, Casadevall C, Zamarron A, Bernues M, Richard S, Lips CJ, Walther MM, Tsui LC, Geil L, Orcutt ML, Stackhouse T, Lipan J, Slife L, Brauch H, Decker J, Niehans G, Hughson M, Moch H, Storkel S, Lerman MI, Marston Linehan W, Zbar B: Germline and somatic mutations in the tyrosine kinase domain of the MET proto-oncogene in papillary renal carcinomas. *Nature Genet* 16:68-73, 1997
 21. Scotlandi K, Baldini N, Oliviero M, Di Renzo MF, Martano M, Serra M, Manara MC, Comoglio PM, Ferracini R: Expression of Met/hepatocyte growth factor receptor gene and malignant behavior of musculoskeletal tumors. *Am J Pathol* 149:1209-1219, 1996
 22. Scotlandi K, Serra M, Nicoletti G, Vaccari M, Manara MC, Nini G, Landuzzi L, Colacci A, Bacci G, Bertoni F, Picci P, Campanacci M, Baldini N: Multidrug resistance and malignancy in human osteosarcoma. *Cancer Res* 56:2434-2439, 1996
 23. Sonnenberg E, Meyer D, Weidner MK, Birchmeier C: Scatter factor/hepatocyte growth factor and its receptor the c-MET tyrosine kinase can mediate a signal exchange between mesenchyme and epithelia during mouse development. *J Cell Biol* 123:223-235, 1993
 24. Straw RC, Withrow SJ, Powers BE: Management of canine appendicular osteosarcoma. *Vet Clin North Am Small Anim Pract* 20:1141-1161, 1990
 25. Straw RC: Tumors of the skeletal system. In: *Small Animal Clinical Oncology*, 2nd ed, pp 287-315. Ed by SJ Withrow and EG MacEwen. Philadelphia, Saunders, 1996
 26. Straw RC, Withrow SJ: Limb-sparing surgery versus amputation for dogs with bone tumors. *Vet Clin North Am Small Anim Pract* 26:135-143, 1996
 27. Weidner KM, Sachs M, Birchmeier W: The Met receptor tyrosine kinase transduces motility, proliferation, and morphogenic signals of scatter factor/hepatocyte growth factor in epithelial cells. *J Cell Biol* 121:145-154, 1993
 28. Withrow SJ, Powers BE, Straw RC, Wilkins RM: Comparative aspects of osteosarcoma: dog versus man. *Clin Orthop* 270:159-168, 1991