



# Three-Dimensional Craniofacial Bone Reconstruction With SmartBone on Demand

Enzo Facciuto, MD,\* Carlo Francesco Grottoli, MSE,† Maurizio Mattarocci, MD,\*  
Fausto Illiano, MD,\* Mara Compagno, PhD,‡ Riccardo Ferracini, MD, PhD,§  
and Giuseppe Perale, MSE, PhD†||

**Abstract:** This is a report of a 34-year-old male lacking of bone development in the frontal and orbital part of the skull due to a surgical removal of a right orbital-front osteoma at the age of 5. The integrity of the craniofacial district was important for the young patient also for social acceptance and self-esteem.

Based on computed tomography patient images, a skull model was reconstructed, both digitally and on 3-dimensional real model, to best design the needed bone graft. Defect wide extension and surface curvature called for the use of the puzzle technique, where the whole graft is composed by several elements, mechanically slotting into each other. The realization was made possible thanks to the use of a composite xenohybrid bone substitute specifically developed for reconstructive surgery (SmartBone, by Industrie Biomediche Insubri SA). SmartBone technology allowed the realization of custom-made grafts which perfectly joined each other and fitted the bone defect thanks to mechanical strength, also at low thicknesses and wide extensions.

The postoperative course was uneventful and computed tomography scans showed new bone formation and complete calvaria continuity already 10 months after surgery, with no signs of inflammation over the entire follow-up.

This case study represents a proof of concept that SmartBone on Demand custom-made bone grafts, together with puzzle technique, are effective, easy to handle and provide final excellent functional and aesthetic results.

**Key Words:** Bone substitute, osteoma, reconstructive surgery, xenograft

From the \*AORN Antonio Caldarelli Napoli UOSC of Maxillo-Facial Surgery; †Industrie Biomediche Insubri SA, Mazzovico-Vira, Switzerland; ‡Center for Research and Medical Studies, AOU Città della Salute e della Scienza, Turin; §Department of Surgical Sciences (DISC), Orthopaedic Clinic, IRCCS AOU San Martino, Genoa, Italy; and ||University of Applied Sciences and Arts of Southern Switzerland (SUPSI), Manno, Switzerland.

Received June 15, 2018.

Accepted for publication November 8, 2018.

Address correspondence and reprint requests to Carlo Francesco Grottoli, MSE, Via Cantonale 67, CH-6805 Mezzovico-Vira, Switzerland;  
E-mail: carlo.grottoli@ibi-sa.com

GP is among shareholders of Industrie Biomediche Insubri SA, the Swiss Company owning intellectual property rights on SmartBone, manufacturing and commercializing it, including its custom-made line SmartBone on Demand, that was investigated in this study. CG works for the same company. RF is external clinical advisor to the same company.

The other authors report no conflicts of interest

Copyright © 2019 by Mutaz B. Habal, MD

ISSN: 1049-2275

DOI: 10.1097/SCS.0000000000005277

(*J Craniofac Surg* 2019;30: 739–741)

Bone defects in the craniofacial area are a clinical challenge and can be the result of severe trauma, congenital malformations, or tumor resection. Autologous bone graft is considered the gold standard for reconstruction because it possesses the prerequisite properties for the successful incorporation of a grafting material and for bone healing, being both osteoconductive and osteoinductive. However, the main limitations of using autografts bone grafts concern the size of the donor site (bone may not always be readily available in case the site involved is quite large) and donor-site morbidity risk that might follow.<sup>1–3</sup> Hence, an alternative approach is represented by tissue engineering solutions, where a range of biomaterials, bone forming cells, and growth factors are combined, aiming at reconstructing and regenerating missing tissue.<sup>4</sup> Tissue-engineered constructs are temporary substitutes developed to treat damaged or lost tissue. Particularly, resorbable synthetic scaffold materials for secondary cranial reconstruction have evolved over time, and recent advances in tissue-engineering approaches have clearly shown the potential benefits of the usage of 3-dimensional (3D) biomaterial matrices that stress tissue regeneration rather than tissue replacement, interacting favorably with patient's cells.<sup>5</sup>

Industrie Biomediche Insubri SA (IBI) developed a new technology to improve the properties of naturally derived biomaterials. Indeed, IBI produces SmartBone (SB), a bone substitute specifically developed for regenerative medicine applications with a long track record of clinical applications and a very low susceptibility to infections.<sup>6–10</sup> This innovative scaffold has a composite structure based on a deproteinized bovine-derived bone matrix reinforced with biodegradable aliphatic polymers and bioactive agents. The bovine-derived matrix is mostly mineral and made of calcium hydroxyapatite (HA,  $\text{Ca}_5(\text{PO}_4)_3(\text{OH})$ ) and maintains an adequate 3D structure, with an open-porosity and a biomimetic chemistry that resemble the human bone; biopolymers (poly(L-lactic acid) and poly( $\epsilon$ -caprolactone)) grant impressive good mechanical properties; bioactive agents (RGD-containing collagen fragments, obtained by purified gelatin) promote cell adhesion, proliferation, and high hydrophilicity. Hydrophilicity is a clinical essential feature for blood absorption and, thus, sparking several growth factors and biochemical signaling molecules, hence enhancing and speeding up graft integration and remodeling once placed into target host site. The polymers degrade by hydrolysis into nontoxic, natural metabolites, which are eventually eliminated from the body in the form of carbon dioxide and water.

Here, we report the case of a craniofacial bone reconstruction with SB, where the bone defect in the skull was left behind after the surgical removal of a voluminous right orbital-front osteoma. Osteomas are benign mature bony growths arising from osteoblasts, seen almost exclusively in bones formed in membrane (eg, the skull).<sup>11,12</sup> They represent the 3rd most common benign neoplasm of bone occurring predominantly in young males.<sup>13</sup>

Surgical intervention is generally indicated for patients whose pain is unresponsive to medical therapy or cannot tolerate prolonged use of nonsteroidal anti-inflammatory drugs and in those cases where bone growth is severe and deforms the shape of the face or for those who are not amenable to activity restrictions.<sup>14</sup>

**CLINICAL REPORT**

The AORN “Antonio Cardarelli” of Naples (Italy) received a 34-year-old male who presented a deficit of the frontal scale and of the supraorbital right arch caused by a frontal and orbital craniotomy he underwent at the age of 5, to remove a voluminous right orbital-front osteoma.

The craniotomy led to the lack of bone development in the frontal and orbital part, generating a partial thickness skull defect. In particular, the patient showed a bone defect in the frontal bone of the skull, with evident flattening-tapering of the orbital-front draft, greater than the right 1 and in the median portion with coronal scar outcome of the previous intervention, “migrated” forward in the course of cranial development (Fig. 1: computed tomography [CT] scan at diagnosis before reconstructive surgery, where bone lack is well evident, as well as also 2 small bone perforations). Being a case of partial thickness cranioplasty allowed avoiding all those concerns related to direct dura contact, typical of full thickness skull defects reconstructions, such as pulsating effect, cerebral related complication, infections, etc.<sup>15</sup>

The SB technology allowed the realization of custom-made grafts which perfectly fitted the bone defect, being an onlay graft reconstruction. A 2 parallel-way approach was followed to design the custom-made grafts, according to previous published works,<sup>8</sup> both using digital planning and 3D real modeling. The CT images were used to create a virtual skull model to support graft design (using platform Mimics Innovation Suite, by Materialise, Belgium). Defect wide extension and surface curvature called for the use of the puzzle technique, where the whole graft is composed by several elements, mechanically joining into each other. Case complexity further called for 3D casting of patient skull and all graft elements, to allow a very precise 3D real model verification and a better surgical planning.<sup>8</sup>

This puzzle technique approach was needed to respect the geometry of the configuration of the bone in the region of interest, in particular concavity, convexity, and differences in thickness. The puzzle model was built, as shown in Figure 2, to avoid loss of material during the manufacture and to rebuild the skull anatomy as faithfully as possible. Once finely tuned and defined, the stereolithographic files were sent to the milling machine software and SB blocks were milled giving the shaped bone grafts, that is, custom-made patient-specific bone grafts, also known as SmartBone on Demand.

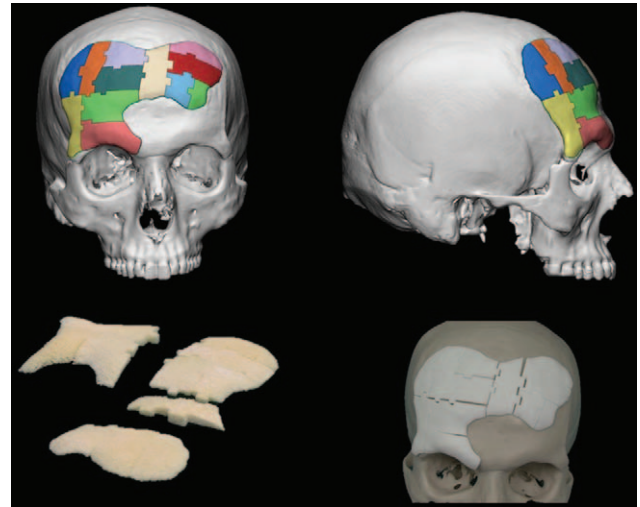


FIGURE 2. Digital design of the puzzle model, puzzle model 3-dimensional printed and SmartBone on Demand grafts ready for the surgery.

Coronal incision was performed along the existing scar from previous surgery to detach the skin until complete exposure of skull bone. Before grafting, each SB element was deeply soaked in the patient’s blood to allow a faster osteointegration process.<sup>8</sup> Microcanalization of receiving site was performed to enhance graft acceptance by host bone.<sup>7</sup> Graft elements were then placed starting from the orbital portion, following planned scheme. Where needed, some graft elements were stabilized onto receiving substrate with microscrews, aiming at gaining high stability of the whole graft. Once all bone graft elements were firmly in place, drainage was placed and scalp tissues were restored and duly sutured.

Postoperative healing was uneventful. Clinical follow-up at different time points postsurgery was conducted to monitor the healing process in terms of volume increase of new bone. No signs of inflammation were ever detected. The CT examination after 11 days showed an initial satisfactory formation associated with good volumetric increase. At 70 days postoperation the incision was barely visible with a stable and satisfactory healing. After 180 days the coronal incision was not visible, with regular regrowth of hair, no signs of reabsorption, stable volumetric increase, and positive feedback from the patient.

The CT scans 10 months postoperatively showed a marked ossification in the defect areas (Fig. 3). Notably, the initial volume of SB implanted was about 29cc, which after 10 months allowed the

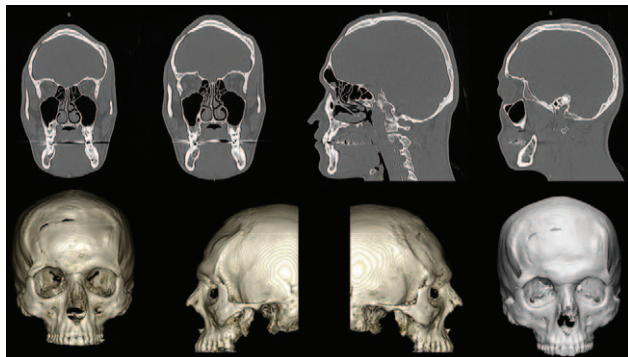


FIGURE 1. Computed tomography scans at diagnosis before reconstructive surgery.

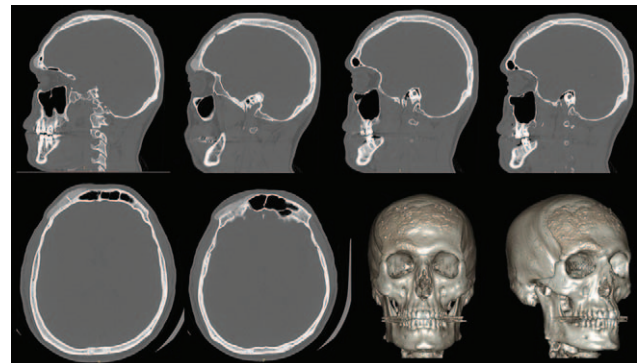


FIGURE 3. Computed tomography scans 10 months postoperatively showed a marked ossification in the defect areas.

formation of at least 16cc of new bone on the defect zone: this estimation is however a minimum as it is complex to precisely distinguish newly formed bone from the preexisting structures, given the high integration capability of SmartBone. Indeed, high stability during all follow-up allowed good integration of the grafted material and a robust thickness increase was gained: the patient showed good and satisfactory reconstruction of the frontal and right orbital bones, which was the final surgical aim. No signs of inflammation or rejection of the material were reported.

## DISCUSSION

Craniofacial bone-tissue engineering is complex and challenging, due to the necessity to restore both sophisticated physiological structures and aesthetic characteristics, avoiding any possible increased stress on the patient. The surgical procedure can be carried out with autogenous tissue (eg, calvarium, rib, iliac crest), allogeneic implants (such as autolyzed antigen-extracted allogeneic AAA-bone, lyophilized cartilage) or alloplastic material (methacrylate, hydroxyapatite, titanium implants, and mesh systems). Each of these solutions is still much controversial because each possible option has advantages and disadvantages in its use, concerning, for example, amount of tissue required, autograft availability and morbidity of donor-site risk, risk of infection, possibility of graft rejection or resorption, etc. However, more recent studies have shown the potential benefits of using a tissue engineering approach, including reduced donor-site morbidity, shorter operative time, decreased technical difficulty of the repair, and, most importantly, the ability to closely mimic the in vivo microenvironment in an attempt to recapitulate normal craniofacial development.<sup>16–18</sup>

Besides radiologic difficulties in properly computed volumetric analysis, a wide fraction of grafted SmartBone resulted converted into newly formed bone and the patient showed a stable and satisfactory reconstruction of the frontal and right orbital bones. Although anatomy was correctly restored, those results most likely reflect the large extension of the implant site, which requires a longer time-window for complete remodeling.

The reconstructive approach used in this study confirms that surgically perforated cortical bony bed, in the onlay setting of xenografts, promotes migration of progenitor cells into the graft material which serves as a scaffold for neo-autogenous bone growth. Here SB biologic performances, high volumetric stability, and high mechanical characteristics allowed benefitting at best from these surgical premises, robustly promoting bone regeneration via remodelling of grafted material.

Overall, the clinical results on this patient after reconstruction of his important craniofacial defect with SB implant, using digital manufacturing approach, were good and this surgery surely represents an advance in terms of both medical technique for the surgeons and as life benefit for the patient. Custom-made SB on Demand grafts manufactured over real models, such as the one described in this study, proved to be effective and feasible. Moreover, our data further proved that SB allowed effective bone regeneration and the restoration of the patient's anatomy in the defect area in about 10 months, without registering any side effect.

We can conclude that the advantages of the usage of custom-made SB grafts in the craniofacial reconstruction surgery include a stable 3D reconstruction of complex anatomic structures, an immediate availability with no donor-site morbidity (as bone or cartilage grafts were not necessary).

## REFERENCES

1. Campana V, Milano G, Pagano E, et al. Bone substitutes in orthopaedic surgery: from basic science to clinical practice. *J Mater Sci Mater Med* 2014;25:2445–2461
2. Hannink G, Arts JJ. Bioresorbability, porosity and mechanical strength of bone substitutes: what is optimal for bone regeneration? *Injury* 2011;42(Suppl 2):S22–S25
3. Mistry AS, Mikos AG. Tissue engineering strategies for bone regeneration. *Adv Biochem Eng Biotechnol* 2005;94:1–22
4. Langer R, Vacanti JP. Tissue engineering. *Science* 1993;260:920–926
5. Roato I, Belisario DC, Compagno M, et al. Adipose-derived stromal vascular fraction/xenohybrid bone scaffold: an alternative source for bone regeneration. *Stem Cells Int*, in press 2018, doi.org/10.1155/2018/4126379.
6. Pertici G, Rossi F, Casalini T, et al. Composite polymer-coated mineral grafts for bone regeneration: material characterisation and model study. *Ann Oral Maxillofac Surg* 2014;2:4
7. Pertici G, Carinci F, Carusi G, et al. Composite polymer-coated mineral scaffolds for bone regeneration: from material characterization to human studies. *J Biol Reg Homeost* 2015;29(Suppl 1):136–148
8. Grecchi F, Perale G, Candotto V, et al. Reconstruction of the zygomatic bone with SmartBone: case report. *J Biol Reg Homeost* 2015;29(Suppl 1):42–47
9. D'Alessandro D, Perale G, Milazzo M, et al. Bovine bone matrix/poly(L-lactic-co-ε-caprolactone)/gelatin hybrid scaffold (SmartBone) for maxillary sinus augmentation: a histologic study on bone regeneration. *Int J Pharm* 2017;523:439–566
10. Stacchi S, Lombardi T, Ottonelli R, et al. New bone formation after transcranial sinus floor elevation was influenced by sinus cavity dimensions: a prospective histologic and histomorphometric study. *Clin Oral Impl Res* 2018;29:465–479
11. da Costa ED, Peyneau PD, Ferreira LM, et al. Clinical implications, diagnosis, and treatment of a giant frontoethmoid osteoma. *Gen Dent* 2018;66:e1–e4
12. Kakkar A, Nambirajan A, Suri V, et al. Primary bone tumors of the skull: spectrum of 125 cases, with review of literature. *J Neurol Surg B Skull Base* 2016;77:319–325
13. Athwal P, Stock H. Osteoid osteoma: a pictorial review. *Conn Med* 2014;78:233–235
14. Yudoyono F, Sidabutar R, Dahlan RH, et al. Surgical management of giant skull osteomas. *Asian J Neurosurg* 2017;12:408–411
15. Gordon CR, Fisher M, Liauw J, et al. Multidisciplinary approach for improved outcomes in secondary cranial reconstruction: introducing the pericranial-onlay cranioplasty technique. *Neurosurgery* 2014;10(Suppl 2):179–189
16. Capanna V, Milano G, Pagano E, et al. Bone substitutes in orthopaedic surgery: from basic science to clinical practice. *J Mater Sci Mater Med* 2014;25:2445–2461
17. Ceccarelli G, Presta R, Benedetti L, et al. Rodriguez y Baena R: emerging perspectives in scaffold for tissue engineering in oral surgery. *Stem Cells Int* 2017;458:5401
18. Colaço HB, Shah Z, Back D, et al. Xenograft in orthopaedics. *Orthopaed Trauma* 2015;29:253–260